

Infectious Bronchitis (IB)

Dr. Bruce Hunter,¹ Ashley Whiteman,¹ Dr. Babak Sanei,² and Al Dam²

Species

Infectious bronchitis (IB) is an infectious viral disease of chickens.

Status in Canada

IB is common and economically important in commercial broiler and laying chicken industries in Canada and globally.

Etiology

IB is caused by a corona virus specific to chickens. There are numerous serotypes of this virus and because it has the ability to mutate and change there are often new variant strains developing.

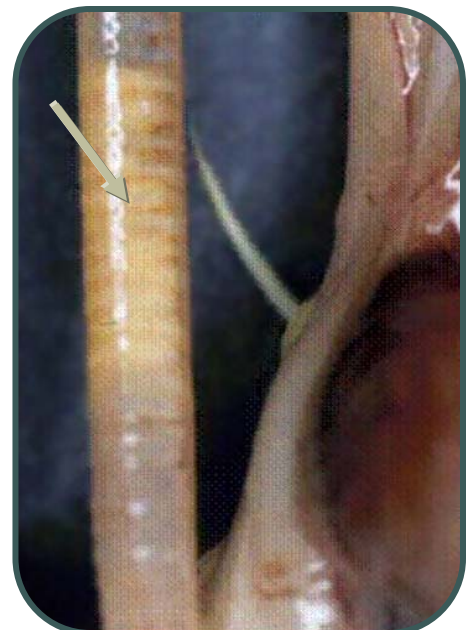
The Disease

This group of corona viruses infect birds through the respiratory system. Once infection in the lungs has been established the virus can be carried to other organs of the body via the blood stream. Most notably the reproductive tract of laying hens and the kidneys of young birds are infected.

Depending on the strain of corona virus and the age of the bird, infection can present in different ways.

In young birds the disease is mainly a respiratory infection with inflammation of the upper respiratory tract particularly the trachea (wind pipe) and bronchi. Affected chicks are chilled, huddle together and sneezing and coughing is common. Affected birds have reduced growth performance. Many birds in the flock will become ill and mortality rates may be

Windpipe (left) from a broiler chick infected with IB virus. The white material (arrow) is a plug of inflammatory and dead cellular debris that has plugged the windpipe and the birds has asphyxiated.



Infectious Bronchitis

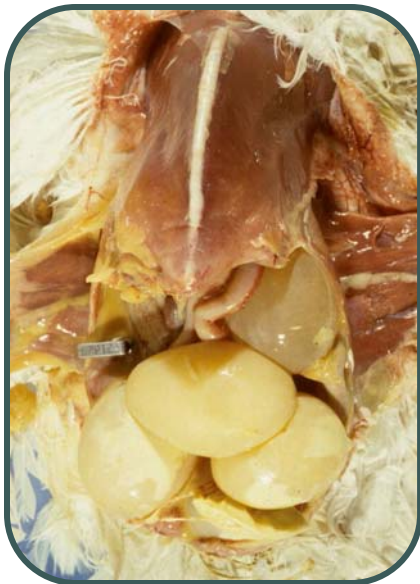


FACTSHEET 6.14
March 2008

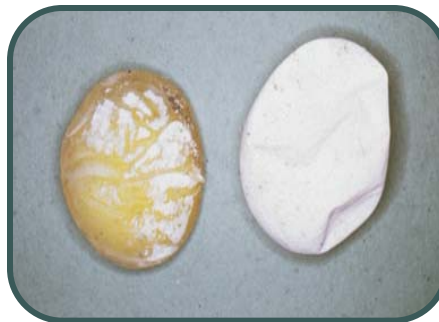high. Sometimes cellular and inflammatory debris from the infection will plug the airways and cause gasping or asphyxiation.

Some strains of the virus grow particularly well in the kidneys (termed nephrotropic). These strains cause kidney swelling and nephritis.

In older birds, IB infections generally cause only mild respiratory infections but the virus travels to the reproductive tract and causes significant decreases in egg production. The virus localizes in the oviduct causing abnormal formation of albumen (egg white) and poor quality eggs that often have abnormal shells. Damage to the oviduct may result in internal laying (eggs in the coelomic cavity of the hen).



Mature laying hen infected with IB. At necropsy the abdomen contained a number of fully formed but improperly shelled eggs (a condition termed internal layer)



Eggs from hen with IB infection showing abnormal shell formation and soft egg shells

Treatment

There is no treatment for affected birds other than supportive care (i.e. good management and nutrition). In young birds with respiratory disease secondary bacterial infections (often *E. coli*) may develop and antibiotics may be helpful.

Prevention

Almost all commercial flocks routinely vaccinate breeder flocks and young birds against this disease. Back yard, specialty and hobby birds are rarely vaccinated. Consult with your veterinarian.



UNIVERSITY
OF GUELPH¹

Ontario²

CONTACT

OMAFRA's
Agricultural
Information
Contact Centre:
1-877-424-1300