

Infectious Laryngotracheitis (ILT)

Dr. Bruce Hunter,¹ Ashley Whiteman,¹ Dr. Babak Sanei,² and Al Dam²

Species

Infectious laryngotracheitis (ILT) is a viral disease of chickens, pheasants, quail and other game birds. There is also a strain of psittacine herpes virus (a separate virus) that causes a similar disease in Amazon parrots.

Status in Canada

ILT is not a common disease in Canada but several outbreaks occur every year. It has significant economic importance particularly in regions of the country where there are numerous commercial poultry farms. The disease is more common in small, backyard flocks where birds are taken to and from bird shows and sales barns.

Etiology

ILT is caused by a herpes virus of chickens.

The Disease

The ILT virus loves the cells lining the upper respiratory tract. It infects these epithelial cells causing severe damage and necrosis. The damaged cells detach and this combined with the severe inflammatory reaction results in mucus and cell debris plugging the windpipe.

The lining of the windpipe may become red, raw and bleeding.

Affected birds are often severely depressed and may sneeze, shake their head in an attempt to clear the debris plugging the windpipe and cough up blood or bloody froth.

*Chicken with ILT coughing blood.
The birds eyes are closed and it is severely depressed.
(Photo from ILT vaccine brochure)*



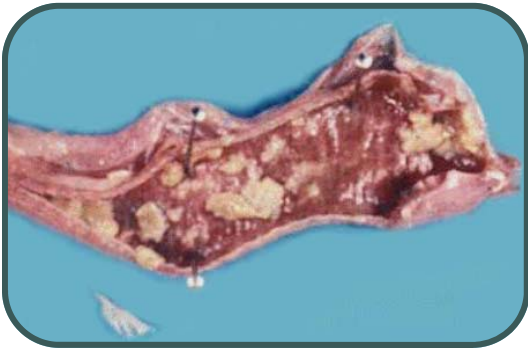
Infectious Laryngotracheitis



FACTSHEET 6.14
March 2008

Oral and nasal discharges and conjunctivitis are often present. Some strains of the virus found in non-vaccinated birds may cause very high mortality rates. All discharges contain infective virus that can infect other birds.

At necropsy birds may have a discharge and reddening of the conjunctiva (area around the eyes). The windpipe also maybe red and sometimes contain blood, froth and exudate.



This trachea (windpipe) from a bird with ILT has been opened to show the red lining and the white plugs of exudate in the tracheal lumen. These plugs are made up of inflammatory debris mixed with sloughed, dead airway lining cells.

A diagnosis can only be confirmed by identifying the herpes virus in infected tissues from the sick bird. Some laboratories grow the virus, others use a combination of molecular techniques or observe characteristic microscopic changes including typical intranuclear inclusion bodies (virus particles) in the affected cells lining the respiratory tract.

Treatment

There is no treatment for this disease. A decision needs to be made whether or not to cull the birds. Recovered birds will be immune to further infection but will carry the virus for a long period and will be a potential source of infection for other flocks or new unvaccinated birds brought into the flock. Sometimes treating with antibiotics will help prevent secondary bacteria diseases from occurring. Consult with your veterinarian.

Prevention

In the commercial poultry industry vaccination of breeder flocks and egg laying flocks is routinely done (eye drop technique). However, small farm flocks and show birds are rarely vaccinated because the vaccine comes in large multi-dose vials making it impractical and costly to vaccinate small numbers of birds. However, good biosecurity and careful purchase of birds (from honest sellers who provide a solid history) combined with a 14-21 day isolation and quarantine of all new birds or those that have been taken off the farm (clubs, shows etc.), will help reduce the risk of introducing this disease.



UNIVERSITY
OF GUELPH¹

Ontario²

CONTACT

OMAFRA's
Agricultural
Information
Contact Centre:
1-877-424-1300